

The efficacy of low-level laser therapy for the treatment of myogenous temporomandibular joint disorder

Farzaneh Ahrari · Azam S. Madani ·
Zahra S. Ghafouri · Jan Tunér

Received: 19 September 2012 / Accepted: 18 December 2012
© Springer-Verlag London 2013

Abstract Low-level laser therapy (LLLT) has been commonly used for the treatment of painful musculoskeletal conditions, but the results of previous studies on this subject are controversial. The aim of this study was to evaluate the efficacy of LLLT in the management of patients with myogenous temporomandibular joint disorders (TMDs). In this randomized, double-blind clinical trial, 20 patients with myogenous TMD were randomly divided into laser and placebo groups. In the laser group, a pulsed 810-nm low-level laser (average power 50 mW, peak power 80 W, 1,500 Hz, 120 s, 6 J, and 3.4 J/cm² per point) was used on painful muscles three times a week for 4 weeks. In the placebo group, the treatment was the same as that in the laser group, but without energy output. The patients were evaluated before laser therapy (T1), after six sessions of laser application (T2), at the end of treatment (T3), and 1 month after the last application (T4), and the level of pain and the amount of mouth opening were measured. There was a significant increase in mouth opening and a significant reduction of pain symptoms in the laser group ($p < 0.05$). A similar improvement was not observed in the placebo group ($p > 0.05$). Between-group comparisons revealed no significant difference in pain intensity and mouth opening measurement at any of the evaluation time points ($p > 0.05$). LLLT can

produce a significant improvement in pain level and mouth opening in patients affected with myogenous TMD.

Keywords Temporomandibular disorder · Low level laser therapy · Low intensity laser therapy · Myofacial pain · Myogenous pain · Temporomandibular joint · LLLT · TMD · TMJ

Introduction

Temporomandibular joint disorders (TMDs), the major etiology of non-dental pain in the orofacial area [1, 2], comprise signs and symptoms relating to the masticatory muscles, temporomandibular joint, or both. The Research Diagnostic Criteria for Temporomandibular Disorders (RDC/TMD) [3] classifies TMDs resulting from myofacial disorder as a separate entity with a characteristic feature of pain in the masticatory muscles, which is frequently associated with restricted mandibular movements. Physical treatments usually aim to reduce pain and recover the function of the masticatory system in patients with temporomandibular disorders. Although there is a wide range of physiotherapy modalities for TMD management, low-level laser therapy has gained more popularity than others because of its conservative nature and the analgesic, regenerative, and anti-inflammatory effects in the target tissue. Several mechanisms have been involved in pain reduction and therapeutic effects of low-level lasers, including promoting the release of endogenous opioids, enhancing cell respiration and tissue healing, increasing vasodilatation, increasing pain threshold by affecting the cellular membrane potential, and decreasing inflammation, possibly due to the reduction of prostaglandin E₂ and suppression of cyclooxygenase 2 levels [4–10].

Previous studies demonstrated controversial results regarding the therapeutic efficacy of low-level lasers in the management of temporomandibular joint disorders. A

F. Ahrari (✉) · A. S. Madani (✉)
Dental Research Center, School of Dentistry, Mashhad University
of Medical Sciences, Mashhad, Iran
e-mail: AhrariF@mums.ac.ir
e-mail: MadaniA@mums.ac.ir

F. Ahrari
e-mail: Farzaneh.Ahrari@gmail.com

Z. S. Ghafouri
Mashhad, Iran

J. Tunér
Grängesberg, Sweden

particular problem is that some studies included a combination of muscular-, disc displacement-, and articular-originated TMDs with no interpretation of the treatment response in each subgroup. In a placebo-controlled study on patients with myogenic orofacial pain, Cetiner et al. [11] found a statistically significant improvement in maximal mouth opening and significant reductions in both pain and chewing difficulty in the laser-irradiated group as compared to the placebo group. The study of Carrasco et al. [1] proved the superiority of the active laser probe for decreasing pain in TMD patients, but there was no significant difference between the laser and placebo groups regarding masticatory function. Mazzetto et al. [2] reported a significant improvement in painful symptoms of TMD patients mainly for the active laser group, compared to subjects who received placebo application. Low-level laser therapy (LLLT) has been demonstrated to be as effective or having greater efficacy than transcutaneous electrical neural stimulation [12, 13], microcurrent electrical stimulation [14, 15], and occlusal splint application [16] for TMD management in several studies. However, da Cunha et al. [17] and Emshoff et al. [18] reported that both LLLT and sham LLLT were capable of producing a significant improvement in pain symptoms of TMD patients with no statistical difference between them, implying that laser therapy was not more effective than the placebo application. The meta-analyses performed by Gam et al. [19], McNeely et al. [20], and Petrucci et al. [21] did not prove the beneficial effects of low-level laser therapy on pain that resulted from musculoskeletal [19] or temporomandibular disorders [20, 21].

The present study aimed to investigate the efficacy of LLLT in improving signs and symptoms of patients with myogenous temporomandibular joint disorder, by using the visual analogue scale (VAS) and measurement of mouth opening.

Methods and materials

Twenty patients with myogenic TMD were selected from a pool of patients referred to the Department of Prosthodontics, School of Dentistry, Mashhad University of Medical Sciences. The diagnosis was made through a standard and comprehensive clinical examination based upon the RDC/TMD [3]. The study included subjects suffering from myofacial pain with/without limited mouth opening. Subjects with disc displacement (with/without reduction), arthralgia, or osteoarthritis of the temporomandibular joint and those who received analgesic or antidepressant medicine or underwent any other form of treatment for TMD were excluded from the study. The protocol was approved by the Ethics Committee of Mashhad University of Medical Sciences, and it was registered with the U.S. National

Institutes of Health (NCT01417637). The purposes of the study were described to each participant, and an informed consent was obtained prior to the start of treatment.

The sample consisted of 20 female patients, with a mean age of 35.5 years. They were randomly divided into LLLT (experimental) and placebo (control) groups with 10 subjects each. The patients in the experimental group received treatment from a pulsed 810-nm laser (Mustang 2000+, Moscow, Russia; Fig. 1a). The laser was operated at a peak power of approximately 80 W, average power of 50 mW, pulse repetition rate of 1,500 Hz, pulse length of 1 μ s, and spot size of 1.76 cm² for 2 min per point, giving an effective energy of approximately 6 J and a dose of 3.4 J/cm² to each painful area. The probe was held perpendicularly and with a light pressure on the target tissue. The laser apparatus was calibrated by an external power meter before and 3 months after the study commencement to ensure delivering the desired energy.

The masticatory muscles were evaluated bilaterally with firm and constant pressure to define painful areas. The palpated sites to define tender points were origin, body, and insertion of the masseter muscle; anterior, middle, and posterior portions of the body of the temporalis muscle; and insertion of the internal pterygoid muscle (Fig. 1b). The laser was applied three times a week for 4 weeks on tender points diagnosed at the start of the treatment. In the placebo group, the laser apparatus was turned on, but without energy output. Both patient and laser therapist wore protective glasses during treatment.

The patients were evaluated before laser therapy (T1), after six laser applications (T2), at the end of the treatment (T3), and 1 month after the last application (T4) to determine the level of pain and the amount of mouth opening. The pain intensity was calculated through a VAS, and the patient was requested to mark the perceived pain on a 10-cm scale representing 0 (no pain) at the left and 10 (the worst possible pain) at the right end. The maximum mouth opening was determined with a millimeter ruler, and the maximum distance between the incisal edges of the upper and lower central incisors was measured.

All the evaluations were performed by an independent investigator who had been trained to do these procedures beforehand. To have a double-blind study, neither the patient nor the evaluator was aware of the group the participant was assigned to. After completing the study, the subjects in the placebo group who tended to continue treatment received another form of therapy for TMD (occlusal appliance therapy, laser therapy, or pharmacologic therapy).

Statistical analysis

The VAS scores obtained from each part of the muscles were averaged between the right and left sides to be used

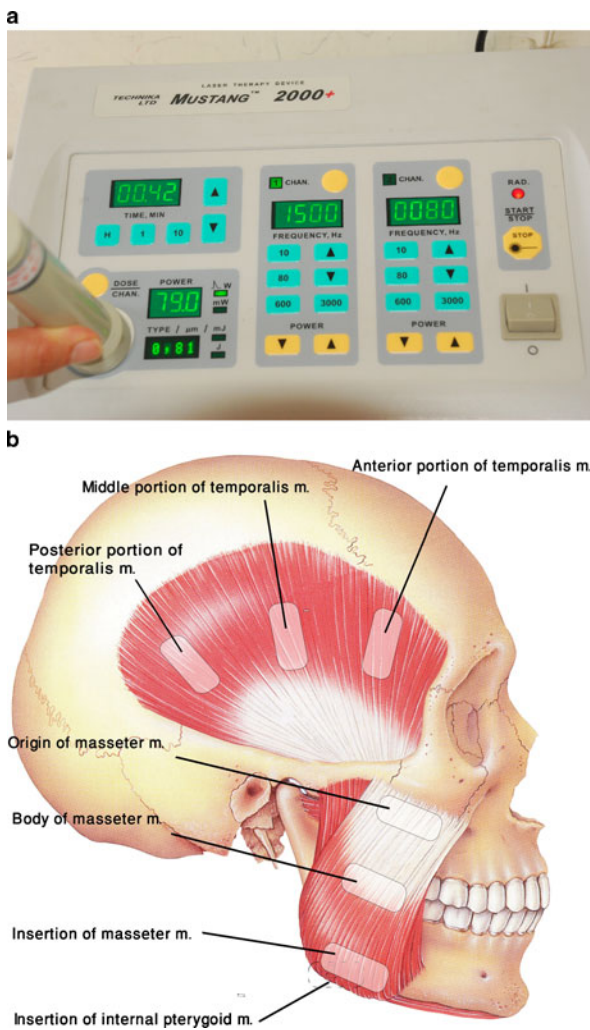


Fig. 1 a The laser apparatus used in this study. b A schematic representation of the points of laser application

for statistical analysis. The normality of the data was confirmed by the Kolmogorov–Smirnov test and the homogeneity of variances by Levene’s test. A repeated measures analysis of variance was used to determine any significant differences in VAS scores and the amount of mouth opening between the study groups and between the different

evaluation times in each group. The statistical calculations were performed using SPSS software (Statistical Package for the Social Sciences, version 16.0, Chicago, IL, USA), and the probability level was determined at $p < 0.05$.

Results

All participants completed the study period. Table 1 presents the mean values and standard deviations (SD) of mouth opening at different evaluation times for the two groups. The initial mouth opening value was 21.3 mm in the laser group and 26.9 mm in the placebo group. After 12 sessions of laser application, there was a 7.6-mm (36 %) increase in mouth opening of the laser group and a 2.0-mm (7 %) increase in mouth opening of the placebo group. The repeated measures analysis of variance indicated that the increase in mouth opening was statistically significant between T1–T3 and T1–T4 time points for the laser group ($p = 0.042$ and $p = 0.031$, respectively), but no significant improvement was found in mouth opening values of the placebo group during the study period ($p > 0.05$).

The masseter muscle gave the most severe pain in these patients. The initial pain values of the body and insertion of the masseter muscle were 4.44 and 3.95 cm, respectively, for the laser group. The corresponding values were 3.33 (body) and 2.31 cm (insertion) for the placebo group. After 12 laser applications, there was a 50 % reduction in VAS score of the body and a 73 % decrease in VAS score of the insertion of the masseter muscle in the laser group. For the placebo group, there was a 24 % decrease in VAS score of the body and a 9 % decrease in VAS score of the insertion of the masseter muscle, following 12 sessions of placebo laser application.

Figures 2, 3, 4, 5, 6, 7, and 8 demonstrate variations of pain intensity in the masticatory muscles of patients in the experimental and control groups. As shown in the figures, the laser group experienced a remarkable decrease in painful symptoms after the 6th (T2) and 12th (T3) sessions, with a

Table 1 Descriptive statistics including mean, standard deviation (SD), minimum (Min) and maximum (Max) values of mouth opening for the laser and placebo groups at different evaluation time points

Group	Treatment evaluation	Mean	SD	Min	Max
Laser	T1	21.3	11.26	0	36
	T2	26.9	7.47	15	35
	T3	28.9	10.14	17	45
	T4	30.4	9.35	17	45
Placebo	T1	26.9	7.78	15	40
	T2	25.4	7.96	9	39
	T3	28.9	7.9	18	42
	T4	29.3	6.46	21	42

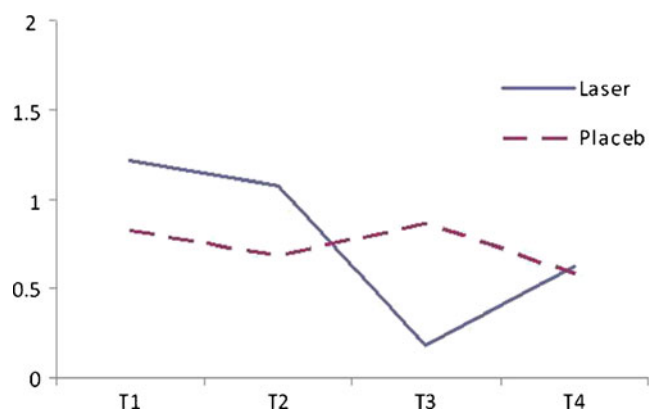


Fig. 2 Line chart indicating VAS values of the origin of the masseter muscle for the laser and placebo groups at different evaluation times. Significant differences were found between T1–T2, T1–T3, T1–T4, T2–T3, and T2–T4 for the laser group

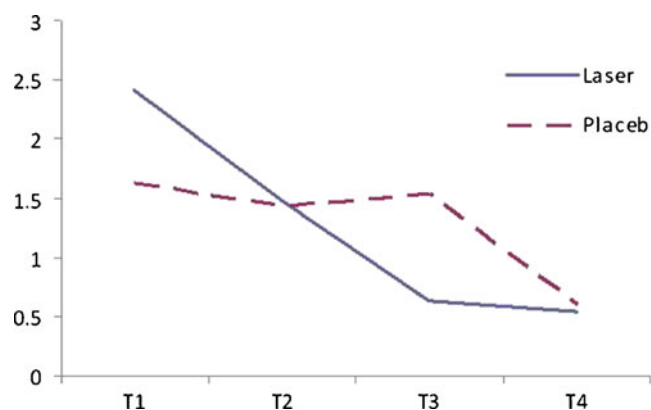


Fig. 5 Line chart indicating VAS values of the anterior portion of the temporalis muscle for the laser and placebo groups at different evaluation times. Significant differences were found between T1–T3 and T1–T4 for the laser group

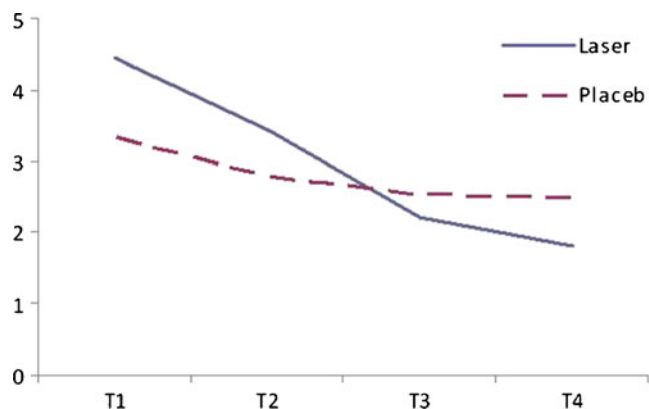


Fig. 3 Line chart indicating VAS values of the body of the masseter muscle for the laser and placebo groups at different evaluation times. Significant differences were found between T1–T3, T1–T4, T2–T3, and T2–T4 for the laser group

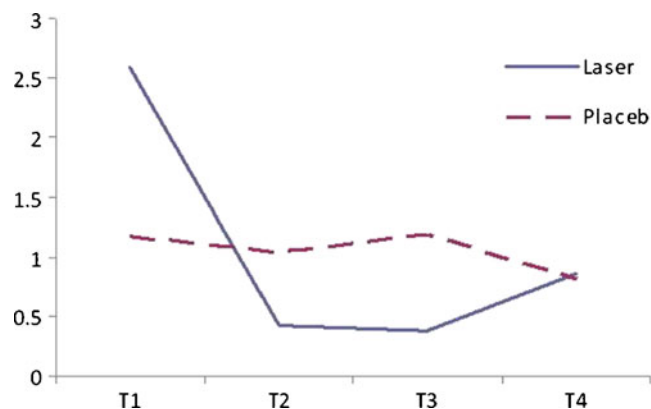


Fig. 6 Line chart indicating VAS values of the middle portion of the temporalis muscle for the laser and placebo groups at different evaluation times. Significant differences were found between T1–T2, T1–T3, and T1–T4 for the laser group

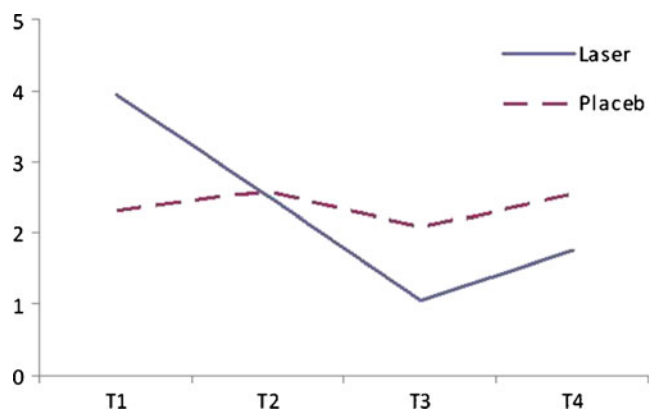


Fig. 4 Line chart indicating VAS values of the insertion of the masseter muscle for the laser and placebo groups at different evaluation times. Significant differences were found between T1–T3 and T1–T4 for the laser group

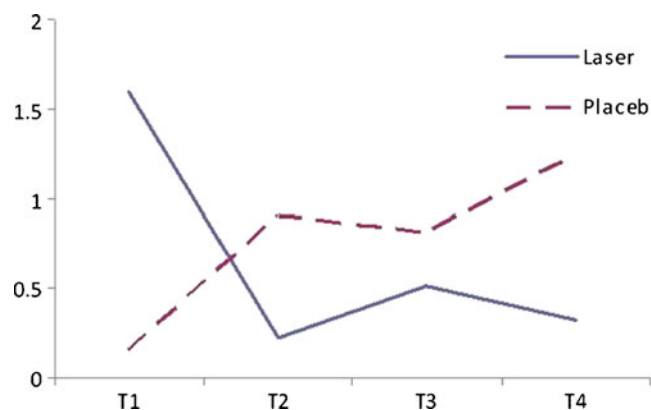


Fig. 7 Line chart indicating VAS values of the posterior portion of the temporalis muscle for the laser and placebo groups at different evaluation times. Significant differences were found between T1–T2 and T1–T4 for the laser group

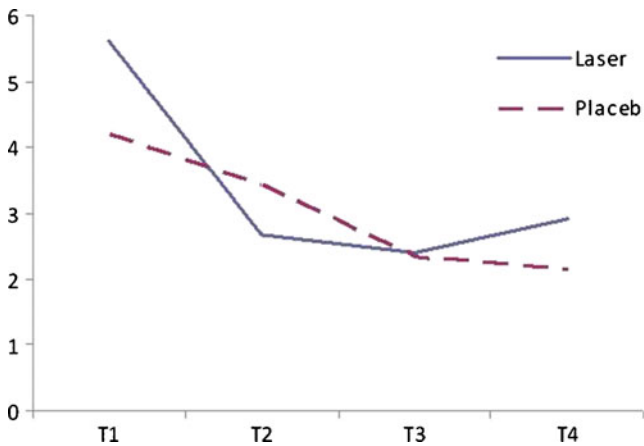


Fig. 8 Line chart indicating VAS values of the insertion of the internal pterygoid muscle for the laser and placebo groups at different evaluation times. Significant differences were found between T1–T2, T1–T3, and T1–T4 for the laser group

small reversal between the end of laser therapy (T3) and 1 month later (T4). For some variables, the statistically significant reduction in pain intensity occurred after 6 sessions of laser therapy, and for other variables, the significant pain relief was obtained after 12 applications. In the placebo group, there was an alternation between improvement and worsening of pain, with no significant reduction between different treatment evaluations ($p > 0.05$) (Figs. 2, 3, 4, 5, 6, 7 and 8). When the laser and placebo groups were compared with each other, no significant difference was found either in mouth opening measurements or in VAS scores at any of the treatment evaluations ($p > 0.05$).

Discussion

The effectiveness of a pulsed 810-nm laser for the treatment of patients with myogenic TMD was investigated in this placebo-controlled study using the parameters of pain intensity and maximum mouth opening. The inclusion criteria were designed so that the effect of interrupting factors on the treatment results was eliminated as much as possible. For example, the patients were restricted from receiving any other form of treatment during the study. Furthermore, patients with myogenic-originated pain were differentiated from arthrogenic cases or those with disc displacement. In some of the previous studies [17, 22–26], TMDs with different origins were included in the study, and this may produce a variation in treatment results. Conti [27] revealed that laser therapy was only effective in improving myogenous pain and it had no effect on reducing pain of arthrogenous cases. A number of studies [28, 29], however, found satisfactory results with both myogenic and arthrogenic TMDs.

In this study, the laser group experienced a 36 % increase in mouth opening after 12 laser applications and a 43 % increase 1 month later. In comparison, the percentages of improvement in mouth opening were 7 % (after 12 placebo laser applications) and 9 % (1 month after the last application) in the placebo group. The improvement was significant for the laser but not for the placebo group, indicating the effectiveness of LLLT to promote mandibular range of motion in TMD patients, as reported by previous authors [11, 20, 29].

Regarding sensitivity to palpation of masticatory muscles, there was a significant reduction in pain symptoms in the laser group, while in the placebo group there was no significant improvement in VAS scores for any of the tested variables. This positive outcome can be attributed to the analgesic effect of low-level lasers, which has been demonstrated in several studies [4–10]. The self-limiting aspect of TMD with periods of symptom improvement could occur in both the laser and the placebo groups. The degree of pain in the control group was fluctuating, showing a mild decrease followed by some increases in painful symptomatology of the masticatory muscles during the course of the study. The placebo effect of LLLT was not demonstrated in this study because the control group did not experience a significant relief in clinical symptoms between the four evaluation time points. This finding corroborates the results of previous authors [1, 11, 23, 26, 27] who reported a significant pain relief for TMD patients treated with the active laser probe but not for the placebo application. The findings of this study, however, are in contrast with those of da Cunha et al. [17], Shirani et al. [30], and Emshoff et al. [18] who reported a significant reduction of pain intensity in both laser and placebo groups, implying that the improvement was mainly due to the placebo effect of laser administration.

Despite the significant improvement in clinical symptoms in the laser group, the between-group comparisons were not statistically significant, neither in muscle tenderness nor in mouth opening at any of the evaluation times. This may be related to the small sample size and the great variation in clinical symptoms of patients in both groups. A number of clinical trials also did not find significant differences between the laser and control groups regarding pain [17, 19, 27, 31] and mandibular range of motion [17, 27] in TMD patients with different etiology. In contrast, several studies reported significantly lower pain and greater mandibular movements in the laser group compared to the placebo application [1, 2, 23, 29, 32–34]. The differences between the outcomes of this study and those of other investigations may be related to the different energy dosage, output power, laser wavelength, and the frequency and number of laser applications as well as to the study design, mode of application, number of subjects, and measurement method.

Some of the previous studies focused on the immediate effect of laser therapy. These studies evaluated pain symptoms after each application [13, 35] or performed LLLT for only one [26], three [27], or four [17] sessions. However, the cumulative effect of laser therapy has been demonstrated in several studies [1, 2, 13]. Kato et al. [13] reported that the positive effects of laser treatment were achieved after several sessions and the immediate effect was not significant. Mazzetto et al. [2] found that the lower sensitivity to palpation of the pressured regions occurred after the eighth application, implying the additive effects of low-level lasers in TMD management. This cumulative effect of LLLT was also observed in the present study because for some variables, the significant improvement in pain was not observed after the 6 but after 12 laser applications. The improvement in mouth opening and pain decrease remained significant 1 month after treatment. A review article regarding the effect of LLLT on chronic joint pain also reported that in most studies with follow-up, pain improvement remained significant for 3 weeks [36].

The laser wavelength is critical to determine light penetration and absorption in biologic tissues. The use of infrared low-level lasers is common in studies regarding TMD because of its good penetration in biologic tissues. Bjordal et al. [36] believed that most of the controversies observed in the studies of low-level laser therapy are probably induced by the disagreement on the dose of laser. In this study, the dose of laser was calculated to be 6 J and 3.4 J/cm² per point, which was consistent with the dosage recommendations of the World Association for Laser Therapy to induce biologic effects in the target tissue [37]. The laser probe was used stationary and with light pressure on the painful areas to prevent reflection and to deliver a defined dose of energy to the affected tissues. Some studies [13, 26] used scanning movements during laser therapy to involve the entire painful area, but calculation of the irradiated dose appeared to be difficult when the probe is moved during therapy, and so in the present study, the different parts of the masticatory muscles were irradiated individually.

The analgesic or anti-inflammatory drugs commonly used for the treatment of TMD patients may induce deleterious health effects. Laser therapy can be regarded as a suitable alternative for conventional treatments of temporomandibular disorders, which enhances the treatment procedure by alleviating the painful clinical symptoms, thus allowing the clinician to remove the underlying etiological factors as soon as possible. Considering the conservative nature of this treatment modality, it appears that further placebo-controlled studies with different laser parameters, larger sample size, and long-term follow-ups are warranted to determine the efficacy of LLLT in the management of

subjects with TMDs of different etiology. The combined effect of other modalities with LLLT and the possible synergism or interaction between them should also be investigated in future studies.

Conclusions

Under the conditions used in this study:

1. Treatment with a pulsed 810-nm low-level laser caused a significant improvement in mouth opening and pain intensity in patients with myogenic TMD. Therefore, LLLT can be considered as a suitable and non-invasive treatment alternative for myogenous pain. The similar improvement was not observed in the placebo group during the course of the study.
2. In the laser group, the improvement in pain and mouth opening remained significant for 1 month after the last application.
3. The statistical analysis revealed no significant difference between the laser and placebo groups regarding pain and mandibular movement, possibly due to the small sample size and the great variation in patients' symptoms.

Acknowledgments The authors would like to thank the Vice-Chancellor for Research of Mashhad University of Medical Sciences for the financial support of this project (grant no. 88563). The results presented in this work were part of a DDS student thesis proposal.

References

1. Carrasco TG, Mazzetto MO, Mazzetto RG, Mestriner W Jr (2008) Low intensity laser therapy in temporomandibular disorder: a phase II double-blind study. *Cranio* 26(4):274–281
2. Mazzetto MO, Carrasco TG, Bidinelo EF, de Andrade Pizzo RC, Mazzetto RG (2007) Low intensity laser application in temporomandibular disorders: a phase I double-blind study. *Cranio* 25(3):186–192
3. Dworkin SF, LeResche L (1992) Research diagnostic criteria for temporomandibular disorders: review, criteria, examinations and specifications, critique. *J Craniomandib Disord* 6(4):301–355
4. Dias FJ, Issa JP, Barbosa AP, de Vasconcelos PB, Watanabe IS, Mizusakiyomasa M (2012) Effects of low-level laser irradiation in ultrastructural morphology, and immunexpression of VEGF and VEGFR-2 of rat masseter muscle. *Micron* 43(2–3):237–244. doi:10.1016/j.micron.2011.08.005
5. Hawkins D, Abrahamse H (2007) Phototherapy—a treatment modality for wound healing and pain relief. *Afr J Biomed Res* 10(2):99–109
6. Mester E, Mester AF, Mester A (1985) The biomedical effects of laser application. *Lasers Surg Med* 5(1):31–39
7. Skinner SM, Gage JP, Wilce PA, Shaw RM (1996) A preliminary study of the effects of laser radiation on collagen metabolism in cell culture. *Aust Dent J* 41(3):188–192

8. Carvalho CM, Lacerda JA, dos Santos Neto FP, de Castro IC, Ramos TA, de Lima FO, de Cerqueira Luz JG, Ramalho MJ, dos Santos JN, Pinheiro AL (2011) Evaluation of laser phototherapy in the inflammatory process of the rat's TMJ induced by carrageenan. *Photomed Laser Surg* 29(4):245–254. doi:10.1089/pho.2009.2685
9. Sakurai Y, Yamaguchi M, Abiko Y (2000) Inhibitory effect of low-level laser irradiation on LPS-stimulated prostaglandin E2 production and cyclooxygenase-2 in human gingival fibroblasts. *Eur J Oral Sci* 108(1):29–34
10. Shimizu N, Yamaguchi M, Goseki T, Shibata Y, Takiguchi H, Iwasawa T, Abiko Y (1995) Inhibition of prostaglandin E2 and interleukin 1-beta production by low-power laser irradiation in stretched human periodontal ligament cells. *J Dent Res* 74(7):1382–1388
11. Cetiner S, Kahraman SA, Yucetas S (2006) Evaluation of low-level laser therapy in the treatment of temporomandibular disorders. *Photomed Laser Surg* 24(5):637–641. doi:10.1089/pho.2006.24.637
12. Nunez SC, Garcez AS, Suzuki SS, Ribeiro MS (2006) Management of mouth opening in patients with temporomandibular disorders through low-level laser therapy and transcutaneous electrical neural stimulation. *Photomed Laser Surg* 24(1):45–49. doi:10.1089/pho.2006.24.45
13. Kato MT, Kogawa EM, Santos CN, Conti PC (2006) TENS and low-level laser therapy in the management of temporomandibular disorders. *J Appl Oral Sci* 14(2):130–135
14. Bertolucci LE, Grey T (1995) Clinical comparative study of micro-current electrical stimulation to mid-laser and placebo treatment in degenerative joint disease of the temporomandibular joint. *Cranio* 13(2):116–120
15. Kogawa EM, Kato MT, Santos CN, Conti PC (2005) Evaluation of the efficacy of low-level laser therapy (LLLT) and the microelectric neurostimulation (MENS) in the treatment of myogenic temporomandibular disorders: a randomized clinical trial. *J Appl Oral Sci* 13(3):280–285
16. Oz S, Gokcen-Rohlig B, Saruhanoglu A, Tuncer EB (2010) Management of myofascial pain: low-level laser therapy versus occlusal splints. *J Craniofac Surg* 21(6):1722–1728. doi:10.1097/SCS.0b013e3181f3c76c
17. da Cunha LA, Firoozmand LM, da Silva AP, Esteves SA, Oliveira W (2008) Efficacy of low-level laser therapy in the treatment of temporomandibular disorder. *Int Dent J* 58(4):213–217
18. Emshoff R, Bosch R, Pempel E, Schoning H, Strobl H (2008) Low-level laser therapy for treatment of temporomandibular joint pain: a double-blind and placebo-controlled trial. *Oral Surg Oral Med Oral Pathol Oral Radiol Endod* 105(4):452–456. doi:10.1016/j.tripleo.2007.09.012
19. Gam AN, Thorsen H, Lonnberg F (1993) The effect of low-level laser therapy on musculoskeletal pain: a meta-analysis. *Pain* 52(1):63–66
20. McNeely ML, Armijo Olivo S, Magee DJ (2006) A systematic review of the effectiveness of physical therapy interventions for temporomandibular disorders. *Phys Ther* 86(5):710–725
21. Petrucci A, Sgolastra F, Gatto R, Mattei A, Monaco A (2011) Effectiveness of low-level laser therapy in temporomandibular disorders: a systematic review and meta-analysis. *J Orofac Pain* 25(4):298–307
22. Carvalho CM, de Lacerda JA, dos Santos Neto FP, Cangussu MC, Marques AM, Pinheiro AL (2010) Wavelength effect in temporomandibular joint pain: a clinical experience. *Lasers Med Sci* 25(2):229–232. doi:10.1007/s10103-009-0695-y
23. Mazzetto MO, Hotta TH, Pizzo RC (2010) Measurements of jaw movements and TMJ pain intensity in patients treated with Ga-AlAs laser. *Braz Dent J* 21(4):356–360
24. Pinheiro AL, Cavalcanti ET, Pinheiro TI, Alves MJ, Manzi CT (1997) Low-level laser therapy in the management of disorders of the maxillofacial region. *J Clin Laser Med Surg* 15(4):181–183
25. Pinheiro AL, Cavalcanti ET, Pinheiro TI, Alves MJ, Miranda ER, De Quevedo AS, Manzi CT, Vieira AL, Rolim AB (1998) Low-level laser therapy is an important tool to treat disorders of the maxillofacial region. *J Clin Laser Med Surg* 16(4):223–226
26. Santos Tde S, Piva MR, Ribeiro MH, Antunes AA, Melo AR, Silva ED (2010) Laser therapy efficacy in temporomandibular disorders: control study. *Braz J Otorhinolaryngol* 76(3):294–299
27. Conti PC (1997) Low level laser therapy in the treatment of temporomandibular disorders (TMD): a double-blind pilot study. *Cranio* 15(2):144–149
28. Fikackova H, Dostalova T, Navratil L, Klaschka J (2007) Effectiveness of low-level laser therapy in temporomandibular joint disorders: a placebo-controlled study. *Photomed Laser Surg* 25(4):297–303. doi:10.1089/pho.2007.2053
29. Kulekcioglu S, Sivrioglu K, Ozcan O, Parlak M (2003) Effectiveness of low-level laser therapy in temporomandibular disorder. *Scand J Rheumatol* 32(2):114–118
30. Shirani AM, Gutknecht N, Taghizadeh M, Mir M (2009) Low-level laser therapy and myofascial pain dysfunction syndrome: a randomized controlled clinical trial. *Lasers Med Sci* 24(5):715–720. doi:10.1007/s10103-008-0624-5
31. Venezian GC, da Silva MA, Mazzetto RG, Mazzetto MO (2010) Low level laser effects on pain to palpation and electromyographic activity in TMD patients: a double-blind, randomized, placebo-controlled study. *Cranio* 28(2):84–91
32. Ilbuldu E, Cakmak A, Disci R, Aydin R (2004) Comparison of laser, dry needling, and placebo laser treatments in myofascial pain syndrome. *Photomed Laser Surg* 22(4):306–311. doi:10.1089/1549541041797878
33. Marini I, Gatto MR, Bonetti GA (2010) Effects of superpulsed low-level laser therapy on temporomandibular joint pain. *Clin J Pain* 26(7):611–616. doi:10.1097/AJP.0b013e3181e0190d
34. Gray RJ, Quayle AA, Hall CA, Schofield MA (1994) Physiotherapy in the treatment of temporomandibular joint disorders: a comparative study of four treatment methods. *Br Dent J* 176(7):257–261
35. Hotta PT, Hotta TH, Bataglion C, Bataglion SA, de Souza Coronatto EA, Siessere S, Regalo SC (2010) Emg analysis after laser acupuncture in patients with temporomandibular dysfunction (TMD). Implications for practice. *Complement Ther Clin Pract* 16(3):158–160. doi:10.1016/j.ctcp.2010.01.002
36. Bjordal JM, Couppe C, Chow RT, Tuner J, Ljunggren EA (2003) A systematic review of low level laser therapy with location-specific doses for pain from chronic joint disorders. *Aust J Physiother* 49(2):107–116
37. http://www.walt.nu/images/stories/files/Dose_table_780-860nm_for_Low_Level_Laser_Therapy_WALT-2010.pdf